

## Surgical Technique

Arthroscopic Transosseous  
Tension Band Rotator Cuff Repair  
with Conexa™ Reconstructive  
Tissue Matrix Reinforcement

conexa™  
*reconstructive tissue matrix*

# SURGICAL TECHNIQUE

---

## Arthroscopic Transosseous Tension Band Rotator Cuff Repair with Conexa™ Reconstructive Tissue Matrix Reinforcement

### Anesthesia:

- Interscalene block at the discretion of the anesthesiologist and patient with general anesthesia with endotracheal intubation.

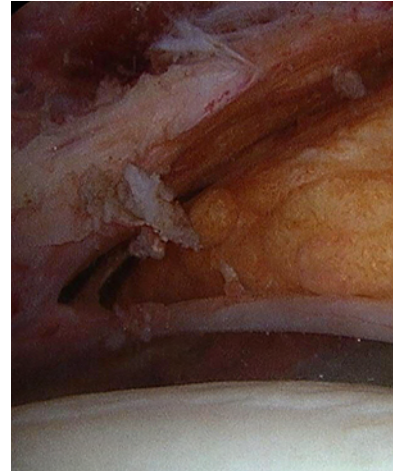
### Positioning:

- Modified Lateral Decubitus
- Knee high TED stockings
- SCD's or foot pumps

### Room Setup and equipment:

- Standard shoulder arthroscopy instruments
- Arthroscopic cannulas:
  - 5.5 mm cannula
  - 8.2 mm cannula with threads
  - 4.5 mm arthroscopic shaver
  - 4.0 mm barrel burr
- Tornier Piton® 2.8 mm double loaded suture anchor
- Tornier Piton® 3.5 mm knotless anchors
- Free high strength sutures
- Conexa™ graft (Tornier)

Conexa™ Reconstructive Tissue Matrix is an intact extracellular matrix which supports cell repopulation and revascularization. Conexa™ functions both as a biologic matrix to support regeneration as well as a biomechanic matrix for load sharing at the repair site\*.



Massive rotator cuff tear.

\*Usage of Conexa™ as a load sharing device has been demonstrated in conjunction with suture fixation as the primary repair.

# SURGICAL TECHNIQUE

---

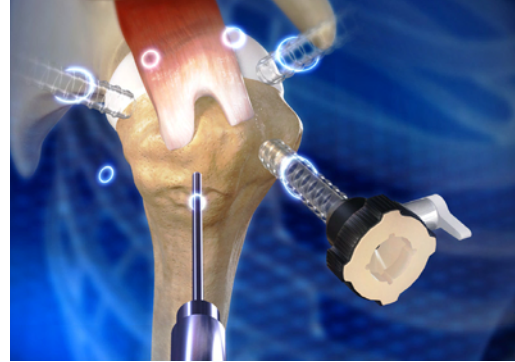## **Procedure:**

The principles are applicable to either the beach chair or modified lateral decubitus position, however, my preference is the modified lateral decubitus position.

After sterile preparation and draping and diagnostic arthroscopy with appropriate treatment of concurrent shoulder pathology, subacromial arthroscopy is performed with the arthroscope in the lateral portal.

An anterior and posterior portal, typically in line with the lateral border of the acromion, are established with 8.25 ID twist in cannulas.

Following subacromial debridement and treatment for other pathology as indicated (acromioplasty, distal clavicle resection, suprascapular nerve resection, etc.), the rotator cuff tear is debrided back to stable and viable tissue. The greater tuberosity footprint is also lightly abraded to restore bleeding bone. No attempt is made to decorticate the footprint (**Fig 1**).



**Fig. 1**

Tear debrided and prepared for repair

# SURGICAL TECHNIQUE

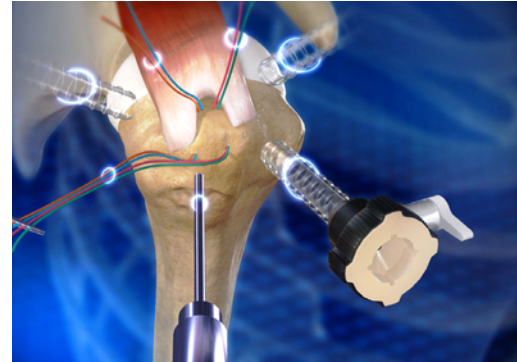
---

The size and pattern of the tear are measured and documented. Preliminary reduction maneuvers are performed to determine the best fit and pattern of the tear to restore equal tension throughout the rotator cuff.

Spinal needle localization is utilized to drill the initial tunnels at the anterior and posterior margins of the footprint immediately lateral to the articular margin using the Arthrotunneler instruments. These portals are percutaneous and typically located at the anterolateral and posterolateral corners of the acromion.

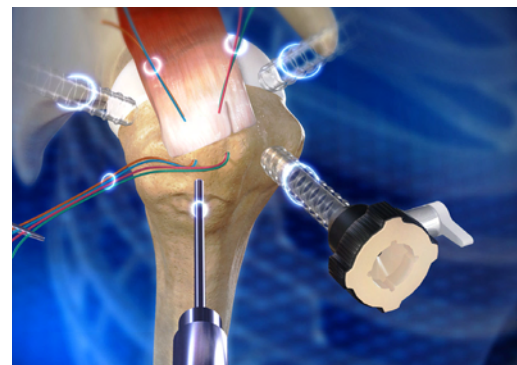An anterolateral portal is established with spinal needle localization to place this distal and parallel to the tuberosity footprint.

An 8.25 mm ID twist in cannula is typically placed through this portal first and then a 2.3 mm beath pin is used to guide the Arthrotunneler into the subacromial space in order to minimize the perforations to the deltoid fascia (**Fig. 2**).



**Fig. 2**

Transosseous tunnels drilled with two braided sutures in each tunnel



**Fig. 3**

Transosseous sutures passed through rotator cuff

# SURGICAL TECHNIQUE

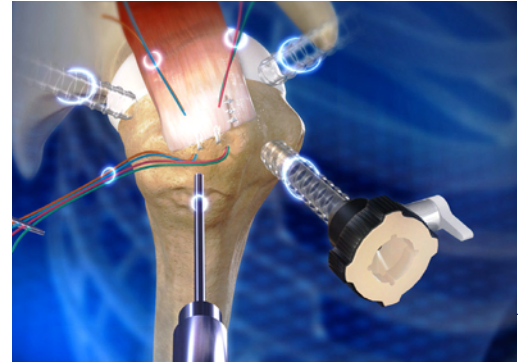
---

Both Tunnels are completed and #2 Braided polyethylene suture of different colors is placed through each tunnel. These sutures are then passed through the rotator cuff at the location best determined to represent the reduced position to minimize the risk of medial tendon tears due to tension mismatch (**Fig 3**).

Both lateral limbs of the tunnel sutures are retrieved through a percutaneous portal distal to the viewing portal to keep them out of the way. These are tagged with a clamp for safety. The medial trans-osseous sutures are also moved to percutaneous portals to keep them out of the way for the tension band repair (**Fig 3**).

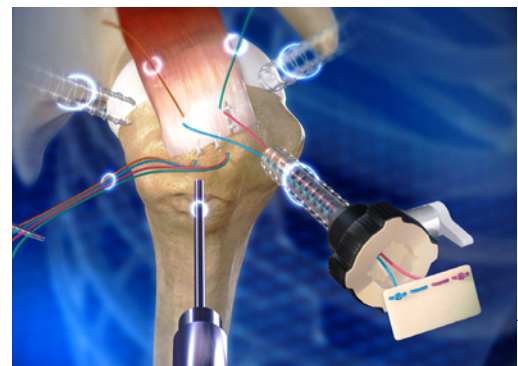
The rotator cuff repair is completed with multiply loaded suture anchors placed distal to the footprint. To maximize tension neutralization each suture is passed through the rotator cuff tendon and tied, prior to placing and tying the next one. This is continued, including placing side to side sutures as needed, until the entire rotator cuff tear has been repaired (**Fig. 4**).

The dimensions between the two medial trans-osseous sutures are recorded as well the distance from these sutures to the far lateral margin of the footprint. These dimensions are transferred to the graft on the back table (**Fig. 5**).



**Fig. 4**

Tension band RCR completed



**Fig. 5**

Graft prepared and medial limb transosseous sutures completed

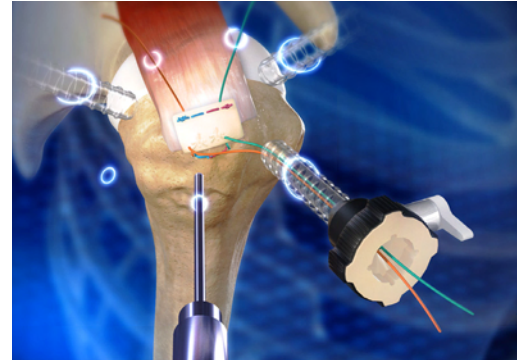
# SURGICAL TECHNIQUE

Once the graft has been cut to size, the two medial trans-osseous suture limbs are brought out the antero-lateral twist-in cannula, keeping them parallel. Each is sutured in a locking running manner at its corresponding site on the graft, while maintaining tension on the graft with clamps.

The two limbs are tied to each other creating a mattress configuration at the medial limb of the graft (**Fig 5**).

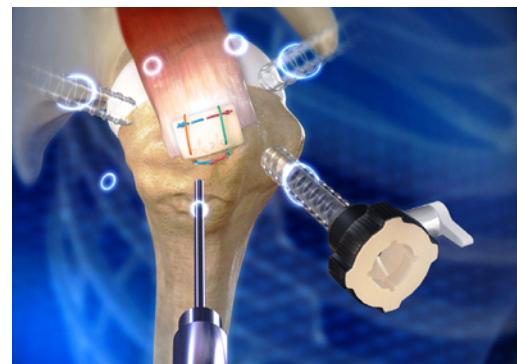The lateral limbs of the trans-osseous sutures are now tensioned and pulled steadily to deliver the graft into the subacromial space. The lateral limbs are retrieved to the antero-lateral cannula and tied over the bone bridge to provide uniform compression at the medial aspect of the rotator cuff footprint and stabilize the medial limb of the graft (**Fig. 6**).

The graft is now draped and tensioned uniformly to determine the best position for passage of the remaining lateral transosseous sutures. Once the second lateral transosseous sutures are passed through the lateral limb of the graft, each is tied in turn to create a transosseous vertical mattress suture configuration, uniformly tensioning the graft and reinforcing the rotator cuff repair. The transosseous tension band rotator cuff repair with acellular dermal graft reinforcement is complete (**Fig 7**).



**Fig. 6**

Second lateral transosseous sutures passed through lateral limb of graft



**Fig. 7**

Completed transosseous tension band repair with reinforcement graft

# SURGICAL TECHNIQUE

---

## • **Post Operative Care:**

The patient is placed in an abductor pillow type brace for 4 weeks postoperative, performing on gentle pendulum exercises several times each day. No passive motion, including pulleys, wall walks, etc. is utilized. At 4 weeks postoperative, the abductor pillow is discontinued and a supine passive stretching program is initiated focused on gentle multiple session of stretching daily prioritizing deltoid relaxation. No strengthening or upright above shoulder activities are initiated until 12 weeks postoperatively to maximize stress free tendon healing. After 12 weeks postoperatively, activities are progressed based on individualized clinical parameters.

## **Summary:**

Conexa™ Reconstructive Tissue Matrix provides biomechanical support for the repaired tendon. It also supports tissue regeneration instead of scarring at the repair site.

Conexa™ should be sutured to the repair site under tension to provide supplemental load sharing across the standard tendon repair to reinforce the initial stiffness of the repair and minimize early gap formation.

Conexa Reconstructive Tissue Matrix can also be used for repair of the following tendons:

- Biceps Tendon
- Patellar Tendon
- Quadriceps Tendon
- Achilles Tendon

## NOTES

---

## conexa™ reconstructive tissue matrix

Product Item No.	Product Description
<b>conexa™ 100</b>	
BCP 020410	Conexa 100 – 2cm x 4cm
BCP 040410	Conexa 100 – 4cm x 4cm
BCP 060610	Conexa 100 – 6cm x 6cm
BCP 051010	Conexa 100 – 5cm x 10cm
<b>conexa™ 200</b>	
BCP 030320	Conexa 200 – 3cm x 3cm
BCP 050520	Conexa 200 – 5cm x 5cm
BCP 051020	Conexa 200 – 5cm x 10cm



Distributed by:

Tornier, Inc.  
Edina, MN 55435  
USA  
+1 888 867 6437  
+1 281 494 7900  
[www.tornier.com/us](http://www.tornier.com/us)

Manufactured by:

LifeCell, Corp.  
One Millennium Way  
Branchburg, NJ 08876  
USA

©2011 Tornier, Inc. All rights reserved.

Tornier is a registered trademark of Tornier, Inc. Conexa is a trademark of Lifecell Corporation.