

Technical Note

Arthroscopic Decompression of a Bony Suprascapular Foramen

Vivek Agrawal, M.D.

Abstract: Arthroscopic decompression of the suprascapular nerve by transection of the transverse scapular ligament has only recently been described. Arthroscopic decompression of a bony suprascapular notch foramen has not been previously reported. This article presents a case report and outlines an arthroscopic technique to safely decompress a bony suprascapular notch. In the subacromial space, a lateral portal is used for viewing and a posterior portal for instrumentation. The medial wall of the subacromial bursa located behind the acromioclavicular joint is debrided with the shaver facing laterally and superiorly. The posterior acromioclavicular artery is routinely coagulated. A superomedial portal is now established using spinal needle localization. A smooth 5.5-mm cannula is placed in this portal and the coracoclavicular ligaments (trapezoid and conoid) are followed to the coracoid. The smooth cannula serves nicely to sweep and retract the suprascapular artery and associated fibrofatty tissue from the field of view while allowing instrumentation and visualization of the suprascapular notch. The course of the suprascapular nerve and morphology of the notch is confirmed. A Kerrison punch rongeur, routinely used in spine surgery, is introduced through the superomedial portal and a notchplasty is performed safely, allowing decompression of the suprascapular nerve. **Key Words:** Arthroscopic technique—Shoulder pain—Suprascapular foramen—Suprascapular nerve—Suprascapular notch.

The suprascapular notch (SSN), located medial to the coracoid at the anterior and superior border of the scapula, is a potential site of compression of the suprascapular nerve (SN). First described in 1936 by Thomas,¹ it continues to be an often overlooked cause of shoulder pain and dysfunction. Many etiologies have been associated with SN entrapment, including blunt trauma, rotator cuff tear, instability, compressive lesions such as ganglion cysts, passage of the suprascapular artery through the SSN, crutch use, repetitive traction injury in athletics, and variations in SSN morphology, including a bony foramen.² Multiple reports have only recently described techniques for minimally invasive re-

lease of the transverse scapular ligament, further raising awareness of SN entrapment as an overlooked cause of chronic shoulder pain.³⁻⁶ Arthroscopic decompression of a bony SSN foramen has not been previously reported. We present a case report and outline a technique to permit the arthroscopic surgeon to safely address bony stenosis of the SN at the SSN.

SURGICAL TECHNIQUE

A 41-year-old woman was referred to our shoulder clinic with a 7-year history of persistent shoulder pain that started after she jerked her shoulder pulling on a cart loaded with books. She had been evaluated by multiple orthopaedic surgeons over the past 7 years and had 4 previous shoulder operations without relief of her postinjury pain. Initial examination of the patient at our clinic was significant for posterior and superior shoulder pain without evidence of cervical pathology, instability, or labrum pathology. Suspicious of occult suprascapular neuropathy, an electro-

From The Shoulder Center, Zionsville, Indiana, U.S.A.

The author reports no conflict of interest.

Address correspondence and reprint requests to Vivek Agrawal, M.D., The Shoulder Center, 10801 N. Michigan Rd., Ste. 100, Zionsville, IN 46077, U.S.A. E-mail: DrAgrawal@TheShoulderCenter.com

© 2009 by the Arthroscopy Association of North America

0749-8063/09/2503-8281\$36.00/0

doi:10.1016/j.arthro.2008.06.014

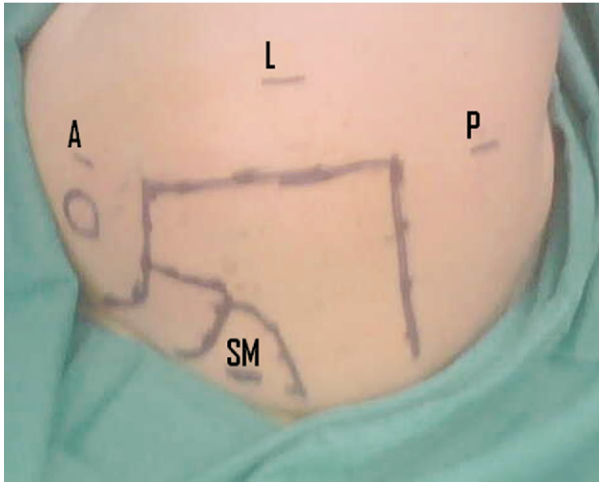


FIGURE 1. Lateral decubitus position with portals for suprascapular notch approach outlined. (A, anterior portal; L, lateral portal; P, posterior portal; SM, superomedial portal.)

diagnostic study of her upper extremity along with an magnetic resonance arthrogram were recommended. The electrodiagnostic study confirmed neuropathy of the SN at both the SSN and spinoglenoid notch (SGN), consistent with a “double crush” phenomenon.⁷ To further confirm the diagnosis, the patient was referred for a confirmatory selective SN block. The SN block provided excellent but transient relief of her pain. After reviewing the risks, benefits, and options for treatment, including our arthroscopic approach to SN decompression, she wished to proceed with arthroscopic treatment.

The SN was decompressed at the SGN by transecting the spinoglenoid ligament as described by Plancher.⁸ Our approach to visualize the SSN is similar to the approach described by Lafosse,⁶ with several modifications. We use a semilateral decubitus position for shoulder arthroscopy (Fig 1). The anatomy and vascularity of the subacromial space has been elegantly described and is helpful in planning approaches to the SN and medial wall of the subacromial bursa.⁹ After completing glenohumeral evaluation and treatment, the arthroscope is introduced into the subacromial space via the posterior portal. An anterolateral portal is established for outflow using an inside-outside technique, ensuring that both portals are within the subacromial bursa. A lateral portal with spinal needle localization is used to ensure an optimal angle of approach. An arthroscopic shaver is introduced through the lateral portal, and the posterior wall of the subacromial bursa is removed to improve visu-

alization. The arthroscope is switched to the lateral portal for viewing and the shaver and radiofrequency device are introduced from the posterior portal. The coracoacromial (CA) ligament is visualized and followed medially. The acromioclavicular (AC) joint is localized but not exposed. The medial wall of the subacromial bursa is now removed to allow access to the SSN. The posterior AC artery is located immediately posterior to the AC joint and is routinely coagulated. A modified superomedial (SM) portal is now established under direct visualization using spinal needle localization.¹⁰ A smooth 5.5-mm cannula is introduced, and the shaver and radiofrequency device are used for further dissection via the SM portal. The CA ligament is followed towards the coracoid. The coracoclavicular ligaments (trapezoid and conoid) are identified. The conoid ligament is visualized and followed inferiorly to its attachment to the coracoid. Frequently, this can be done with a gentle sweeping motion along these ligaments. The coracoid insertion of the transverse scapular ligament is seen perpendicular to the coracoid insertion of the conoid ligament. Use of the shaver and radiofrequency device are restricted to the space lateral to the medial border of the coracoid to avoid injury to the suprascapular artery. Blunt dissection can often proceed inferiorly and medially from the coracoid while maintaining contact with bone, allowing the SSN, suprascapular artery, and SN to be visualized and safely retracted without directly disturbing these structures. The morphology of the SSN is now defined (Fig 2). In most cases, the transverse scapular ligament is easily transected via the SM portal using arthroscopic scissors. For a bony or stenotic SSN foramen, as in the present case, a Kerrison punch rongeur is introduced through the SM portal to perform a foraminotomy. The superior and lateral walls of the SSN are decompressed in a controlled manner.¹¹ Kerrison rongeurs are routinely used for bone removal in spine surgery and are available in multiple sizes and configurations in most facilities. Upon completion of the SSN decompression, a probe is used to confirm mobility of the SN by lifting it out of the SSN. Postoperatively, the patient reported resolution of her longstanding posterior and superior shoulder pain and was extremely pleased with her outcome.

DISCUSSION

Although the prevalence of suprascapular compression neuropathy is thought to be rare, its role in

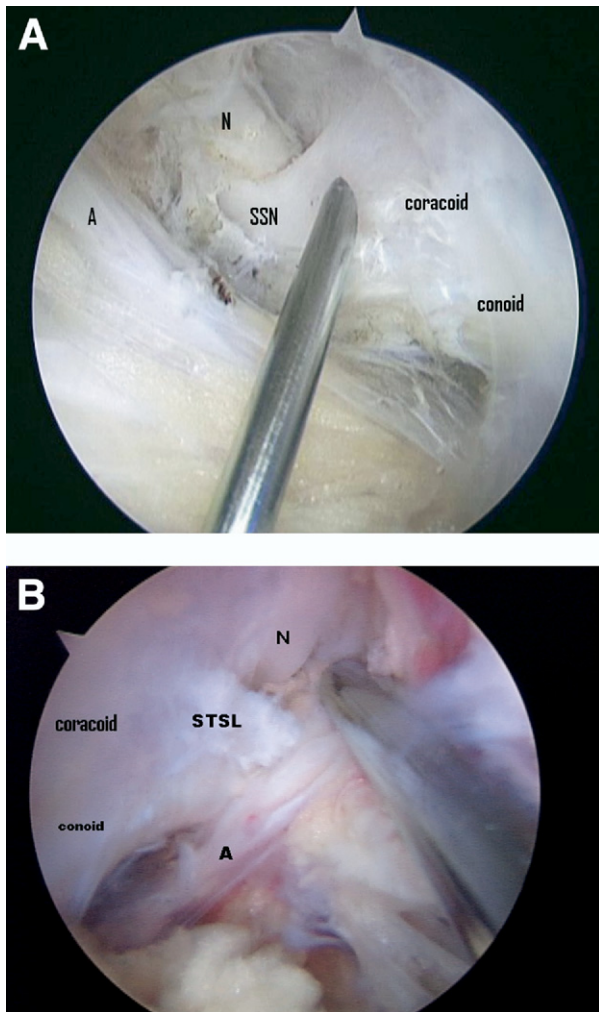


FIGURE 2. (A) Right shoulder with bony suprascapular notch foramen. (B) Left shoulder with more commonly encountered superior transverse scapular ligament. (A, suprascapular artery; N, suprascapular nerve; STSL, superior transverse scapular ligament; SSN, suprascapular notch.)

shoulder pain and dysfunction is probably underappreciated. The morphology, particularly a stenotic or bony notch of the SSN, may be associated with a predilection to suprascapular nerve injury.² The transverse scapular ligament, despite connecting 2 regions of the same bone, has been shown to have fibrocartilage entheses, indicating that it experiences both compressive and tensile loading.¹² Consistent with these findings, bony bridges at the SSN are also seen more frequently with increasing age.¹³ Of the 700 specimens examined by Edelson,¹⁴ 11.8% had a completely or partially ossified transverse scapular ligament. In a recent update to the classification proposed by Ren-

gachary et al.,² Natsis et al.¹⁵ examined 423 scapulas and noted an 8% incidence of a bony foramen (types IV and V).

From May 2007 to May 2008, 2 of the 44 patients seen at our tertiary care shoulder clinic for arthroscopic SN decompression at the SSN had a bony SSN foramen. To establish the diagnosis of suprascapular neuropathy, we request electrodiagnostic studies after a detailed clinical evaluation to confirm the diagnosis and predict an expected outcome for treatment.¹⁶ In our experience, electrodiagnostic studies of the shoulder girdle are highly variable in diagnostic quality. Therefore, a single experienced examiner familiar with the electrodiagnostic criteria for SN pathology performed most of the studies.¹⁶ For patients with isolated SN lesions, we often use a selective SN block as a further diagnostic and confirmatory measure before proceeding with arthroscopy.

Several techniques for arthroscopic transverse scapular ligament release along with early clinical results have been recently reported.^{3-6,10} In the preliminary clinical series of 10 patients reported by Lafosse et al.,⁶ none had SN compression as a result of bony stenosis. However, he recommended using an arthroscopic burr to address bony stenosis.⁶

This technique has several advantages: the SM portal is a safe distance from the SN and relatively familiar to most arthroscopic surgeons.¹⁰ The SM portal allows a more direct approach to dissection of the deep surface of coracoclavicular ligaments and the SSN, and the smooth cannula in this portal serves nicely as a soft tissue retractor avoiding the need for another portal. Kerrison punch rongeurs are specifically designed for decompression of spinal stenosis and uniquely suited to arthroscopic decompression of suprascapular nerve stenosis. For our initial case with a bony SSN foramen, we started with a burr as suggested by Lafosse; however, given the proximity of the neurovascular structures, we felt that the Kerrison punch offered a greater margin of safety and control. We completed the case with the Kerrison punch and used it exclusively for the second patient with a bony SSN. The technique is adaptable and appropriate for variations in SSN anatomy.

Arthroscopic decompression of the suprascapular nerve with a bony SSN foramen has not been previously reported. This technique provides the arthroscopic surgeon another approach to safely decompress the suprascapular nerve at the SSN in cases of bony stenosis using commonly available instruments.

REFERENCES

1. Thomas A. La paralysie du muscle sous-épineux. *Presse Med* 1936;64:1283-1284.
2. Rengachary SS, Burr D, Lucas S, Hassanein KM, Mohn MP, Matzke H. Suprascapular entrapment neuropathy: A clinical, anatomical, and comparative study. Part 2: Anatomical study. *Neurosurgery* 1979;5:447-451.
3. Barber FA. Percutaneous arthroscopic release of the suprascapular nerve. *Arthroscopy* 2008;24:236e1-236e4.
4. Barwood SA, Burkhart SS, Lo IK. Arthroscopic suprascapular nerve release at the suprascapular notch in a cadaveric model: An anatomic approach. *Arthroscopy* 2007;23:221-225.
5. Bhatia DN, de Beer JF, van Rooyen KS, du Toit DF. Arthroscopic suprascapular nerve decompression at the suprascapular notch. *Arthroscopy* 2006;22:1009-1013.
6. Lafosse L, Tomasi A, Corbett S, Baier G, Willems K, Gobezie R. Arthroscopic release of suprascapular nerve entrapment at the suprascapular notch: Technique and preliminary results. *Arthroscopy* 2007;23:34-42.
7. Upton AR, McComas AJ. The double crush in nerve entrapment syndromes. *Lancet* 1973;2:359-362.
8. Plancher KD, Luke TA, Peterson RK, Yacoubian SV. Posterior shoulder pain: A dynamic study of the spinoglenoid ligament and treatment with arthroscopic release of the scapular tunnel. *Arthroscopy* 2007;23:991-998.
9. Yepes H, Al-Hibshi A, Tang M, Morris SF, Stanish WD. Vascular anatomy of the subacromial space: A map of bleeding points for the arthroscopic surgeon. *Arthroscopy* 2007;23:978-984.
10. Woolf SK, Guttman D, Karch MM, Graham RD 2nd, Reid JB 3rd, Lubowitz JH. The superior-medial shoulder arthroscopy portal is safe. *Arthroscopy* 2007;23:247-250.
11. Klein GR, Ludwig SC, Vaccaro AR, Rushton SA, Lazar RD, Albert TJ. The efficacy of using an image-guided Kerrison punch in performing an anterior cervical foraminotomy. An anatomic analysis. *Spine* 1999;24:1358-1362.
12. Moriggl B, Jax P, Milz S, Büttner A, Benjamin M. Fibrocartilage at the entheses of the suprascapular (superior transverse scapular) ligament of man—A ligament spanning two regions of a single bone. *J Anat* 2001;199(Pt 5):539-545.
13. Hrdlicka A. The scapula: Visual observations. *Am J Phys Anthropol* 1942;29:73-94.
14. Edelson JG. Bony bridges and other variations of the suprascapular notch. *J Bone Joint Surg Br* 1995;77:505-506.
15. Natsis K, Totlis T, Tsikaras P, Appell HJ, Skandalakis P, Koebke J. Proposal for classification of the suprascapular notch: A study on 423 dried scapulas. *Clin Anat* 2007;20:135-139.
16. Antoniou J, Tae SK, Williams GR, Bird S, Ramsey ML, Iannotti JP. Suprascapular neuropathy. Variability in the diagnosis, treatment, and outcome. *Clin Orthop Relat Res* 2001;386:131-138.